

Original article:

Rare variation of extensor indicis tendon in both forearm

**¹Dr Soumedhik Dey , ²Dr Soma Saha , ³Dr Subhasis Chakraborty, ⁴Dr Gouranga Dutta ,
⁵Dr Sumita Dutta**

¹ Assistant Professor, NRS Medical College , Kolkata, West Bengal

²Associate Professor, CNMC, Kolkata, West Bengal

³Assistant Professor, NRS Medical College, Kolkata, West Bengal

⁴3RD YEAR P.D.T., Department of plastic surgery. I.P.G.M.E& R.

⁵Associate Professor, CNMC, Kolkata, West Bengal

Corresponding author : Dr Soumedhik Dey

Abstract:

The extensor indicis (EI) muscle in the deep layer of the dorsum of the forearm placed medial to and parallel to extensor pollicis tendon. It originates from posterior surface of ulna distal to extensor pollicis longus and adjacent interosseous membrane. During routine dissection, it has been found that there is duplication of the EI tendon in both upper limb inspite of presence of extensor digitorum(ED) tendon.

Key words: extensor indicis, surgery, hand

Introduction:

In human anatomy, the extensor indicis [proprius] is a narrow, elongated skeletal muscle in the deep layer of the dorsal forearm, placed medial to, and parallel with, the extensor pollicis longus. Its tendon goes to the index finger, which it extends. It arises from the posterior surface of the ulna and from the interosseous membrane. Opposite the head of the second metacarpal bone, it joins the ulnar side of the tendon of the extensor digitorum which belongs to the index finger. The extensor indicis extends the index finger, and by its continued action assists in extending (dorsiflexion) the wrist and the midcarpal joints.

□ Anomalous variation of extensor indicis tendon (EI) is very scarce. Anatomical knowledge of such variation should be considered while performing tendon graft surgeries in the hand.

Material and method:

During routine cadaveric dissection classes for the purpose of teaching under –graduate medical students, it was noted in a 67 year old female cadaver fixed in 10% formalin that Extensor Indicis (EI) muscle showed two tendons in both upper limbs running along the forearm beneath extensor retinaculum.

Observation and result:

During routine cadaveric dissection classes for the purpose of teaching under –graduate medical students, it was noted in a 67 year old female cadaver fixed in 10% formalin that Extensor Indicis muscle showed two tendons in both upper limbs running along the forearm beneath extensor retinaculum. Both tendons were long and of similar caliber as they passed distally beneath the bulky Extensor Digitorum tendon . In both limbs it was seen that the tendons

were inserted into the ulnar aspect of dorsal digital expansion of the index finger. When traced upwards it was seen that the tendons originated from distal third of posterior surface of ulna and adjacent interosseous membrane . Throughout the forearm they were separate and parallel to each other only merging together for insertion near capsule of second metacarpophalangeal joint. So this was regarded as a case of duplication of EI tendon occurring normally in both upper limbs of the above said person.

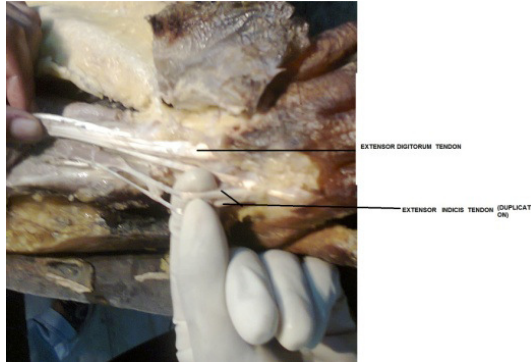
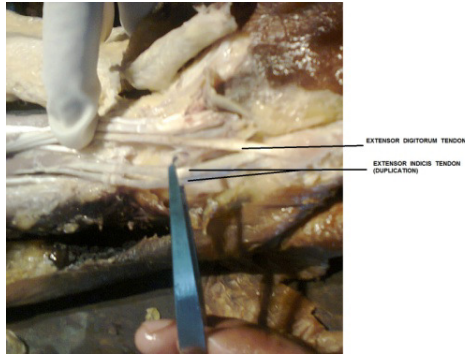
Discussion

Extensor tendons especially the extensor indicis is known for its variations. It occasionally sends accessory slips to extensor tendons of other digits. Rarely it may be interrupted by an additional muscle belly on the back of the hand. The presence of two heads or complete duplication of EI, double tendon of the EI has been reported [1].

EI tendon is meant for extension of index finger and by its continued action it also helps in slight dorsiflexion of wrist and mid-carpal joint. In human anatomy, the extensor indicis proprius is a narrow, elongated skeletal muscle in the deep layer of the dorsal forearm, placed medial to, and parallel with, the extensor pollicis longus. Its tendon goes to the index finger, which it extends. Anatomic variations in the musculotendinous structure of the hand and wrist are particularly important in repairing or reconstruction of hand injuries. We report here an extensor indicis proprius (EIP) tendon with an unusual appearance. Anomalous extensor muscles of the hand that have been reported include anomalous EIP, extensor digitorum brevis manus (EDBM), extensor medii proprius (EMP), extensor indicis et medii communis (EIMC), and accessory belly of the dorsal interosseous muscle [2-6]. Anomalous EIP

muscle has been reported previously [3,4,6]. Tan and Smith [3] reported that the anomalous EIP muscle belly extended beyond the fourth dorsal compartment, especially during full flexion of the wrist. Baker and Gonzalez [6] reported that the majority of the enlarged EIP muscle belly was situated beneath the extensor retinaculum. In addition, the EIP muscle was poorly developed, and this aberrant muscle was thus completely excised. Ritter and Inglis [4] described EIP syndrome, in which was found considerable tenosynovial proliferation surrounding the anomalous EIP muscle. However, the present case is different. In our present case both the tendon of EI were inserted into the ulnar aspect of dorsal digital expansion of the index finger. The index finger has two independent tendons that are the least variable of the extensor tendons [3]. The EIP tendon is clinically significant, in that it is frequently used as a source for tendon transfer. . Total removal of the anomalous EIP muscle creates the risk of losing independent extension of the index finger. So, It may mimic a pathologic mass and is frequently misdiagnosed as a ganglion, tendon sheath cyst, tenosynovitis of the extensor tendons, exostosis, carpal boss, or benign soft-tissue tumor [2,3] Ultrasonography may aid in diagnosis. In conclusion, even though anomalous EIP muscle is relatively rare and rarely causes dorsal wrist pain, awareness of this possible anatomic variation of the extensor tendon is important when considering tendon transfer or for managing hand disease.

The present study reported is a case of duplication of extensor indicis (EI) tendon which knowledge is far essential for tendon graft surgeries.



References

1. Johnson D. Forearm. In : Standring S., Gray's anatomy ; The Anatomical Basis of Clinical Practice. 40th Edn. Edinburgh Scotland, Churchill Livingstone Elsevier; 2008. p 851.
2. Antonio A. Extensor digitorum brevis manus associated with a dorsal wrist ganglion: case report. Clin Anat. 2008;21:794–795
3. Tan ST, Smith PJ. Anomalous extensor muscles of the hand: a review. J Hand Surg Am. 1999;24:449–455. [PubMed]
4. Ritter MA, Inglis AE. The extensor indicis proprius syndrome. J Bone Joint Surg Am. 1969;51:1645–1648. [PubMed]
5. Still JM, Jr, Kleinert HE. Anomalous muscles and nerve entrapment in the wrist and hand. Plast Reconstr Surg. 1973;52:394–400.
6. Baker J, Gonzalez MH. Snapping wrist due to an anomalous extensor indicis proprius: a case report. Hand (N Y) 2008;3:363–365. [PMC free article [PubMed]]